

Management of ureteral avulsion as a complication of ureterorenoscopy

Üreterorenoskopi'nin bir komplikasyonu olan üreter kopmasına yaklaşım

Fikret Fatih Öno¹, Yılören Tanıdır², Alpaslan Akbaş³, Emin Özbek³, Şinasi Yavuz Öno³

¹Ministry of Health Sakarya Training and Research Hospital, Clinic of Urology, Sakarya

²Ministry of Health Diyarbakır Training and Research Hospital, Clinic of Urology, Diyarbakır

³Vakıf Gureba Training and Research Hospital, Clinic of Urology, İstanbul

Abstract

Objective: To review diagnostic and operative considerations in the management of ureteral avulsion resulting from ureterorenoscopy.

Materials and methods: Between 1999 and 2007, three cases of complete ureteral avulsion following ureteroscopic surgery were repaired. Avulsion was recognized perioperatively in two patients undergoing surgery for impacted distal and mid-ureteral stones, and was treated with end-to-end anastomosis in one case, and with psoas hitch in the other. One patient undergoing surgery for a proximal stone in another center was referred five days postoperatively with right flank pain, tenderness, and fever. A percutaneous nephrostomy was placed, and antegrade pyelogram showed a large defect of the mid-ureter. The avulsed ureter was repaired three weeks after the original surgery with a Boari flap extending to the proximal ureter. In all cases, ureteral stent was removed within six weeks of surgery.

Results: Intravenous pyelogram obtained six months after surgery showed ureteral patency in all cases without evidence of dilatation or strictures. Ureteral stricture was not observed during a follow-up period of at least 18 months.

Conclusion: Repair of complete ureteral avulsion following endoscopic surgery is a challenging task which should be tailored according to the individual situation. Boari flap is a versatile technique in the repair of severe ureteral defects, and may eliminate the need for a possible ileal ureteric replacement. Proper ureteroscopic handling is the key to prevention of this catastrophic complication.

Key words: Ureterorenoscopy; ureteral avulsion; reconstructive surgical procedures.

Özet

Amaç: Üreterorenoskopiye bağlı olan üreter kopmasında tanılabilir ve cerrahi yaklaşımların değerlendirilmesi.

Gereç ve yöntem: 1999-2007 yılları arasında üreteroskopik cerrahiye bağlı olarak üreter kopması görülen üç hastanın cerrahi onarımı yapıldı. Hastaların ikisinde impakte distal ve mid-üreteral taş nedeniyle yapılan cerrahi girişime bağlı gelişen üreter kopması perioperatif dönemde tespit edildi ve onarım bir hastada uç-uca anastomoz, diğerinde ise psoas hitch yöntemi ile yapıldı. Başka bir merkezde proksimal taş nedeniyle opere edilen bir diğer hasta postoperatif 5. gün sağ yan ağrısı, hassasiyet ve ateş nedeniyle başvurdu. Perkütan nefrostomi yerleştirildikten sonra çekilen antegrad piyelogramda mid-üreterde geniş bir defekt olduğu saptandı. Kopmuş olan üreter, ilk cerrahi girişimden 3 hafta sonra, proksimal üretere kadar uzanan bir Boari flebi ile onarıldı. Tüm hastalarda üreter stenti cerrahi sonrası 6 hafta içinde çekildi.

Bulgular: Tüm hastalarda cerrahi sonrası 6. ayda yapılan intravenöz piyelogramda dilatasyon ya da darlık olmaksızın üreter bütünlüğü izlendi. Ayrıca üreter darlık en az 18 aylık izlem süresince de saptanmadı.

Sonuç: Endoskopik cerrahiye bağlı tam üreter kopmasının onarımı zor bir girişimdir ve hastaya özel yaklaşım gerektirir. Boari flebi, ileri üreter hasarlarında etkili bir tekniktir ve muhtemel bir ileal üreter replasmanına gereksinimi ortadan kaldırabilir. Ciddi komplikasyonların önlenmesinde en etkili yöntem, doğru üreteroskopik uygulamalardır.

Anahtar sözcükler: Üreterorenoskopi; üreter kopması; rekonstrüktif onarım

Introduction

In 1912, urologist Hugh Hampton Young performed the first ureterorenoscopy in medical history^[1] Since this historic first attempt, urologists have sought a device to inspect and treat upper urinary tract pathology. The first rigid ureterorenoscopy was introduced into clinical practice almost one decade after the flexible ureterorenoscopy was used by Goodman in 1977.^[2-3] Despite our improving knowledge and skills regarding ureteroscopic practice, improper use of this excellent surgical tool is prone to result in serious complications. Herein, we discuss ureteral avulsion, one of the major but rare complications of ureterorenoscopy, and how to handle this challenging problem with reference to three clinical cases.

Materials and methods

Among the 452 ureterorenoscopic stone surgeries performed between 1999 and 2007, two cases of complete ureteral avulsion were encountered as intraoperative complications of an endourological procedure. Another case was referred on the fifth postoperative day from another center as a late diagnosis. All three patients were managed with open reconstructive surgery with ureteral stenting.

Case 1: A 59-year-old man presented three weeks after a four-session extracorporeal shock wave lithotripsy (ESWL) treatment performed in another center. The patient had been treated for an impacted right distal ureteral stone located 3 cm proximal to the ureterovesical junction, and a midureteral stone 2 cm proximal to that, each stone measuring 1.5 cm in diameter. The patient was scheduled for ureteroscopy with a Storz 9.5 Fr semi-rigid ureterorenoscope and pneumatic lithotripsy (Elmed Vibrolith, Elmed Lithotripsy Systems, Ankara, Turkey). The procedure was performed under general anesthesia, and the distal stone was treated without complication; however, instrumentation was extremely difficult during manipulation of the impacted proximal stone. Due to severe edema and obstructed passage, blind attempts at lithotripsy resulted in damage to the ischemic ureteral wall, leading to complete ureteral avulsion, which was recognized after visualizing the proximal region of the impacted area.

Immediately thereafter, a vertical midline abdominal incision was made to reach the retroperitoneum. Upon exploration of the right ureter, a psoas hitch was planned in consideration of the location of the defect (i.e., mid-ureter) and the length of the devitalized segment (2 cm). First, the bladder dome was

completely mobilized to reach the psoas region freely, the proximal ureteric end was partially mobilized, and the defect was repaired with a non-refluxing anastomosis to the psoas hitch (Fig. 1). Intravenous pyelogram (IVP) obtained six months after surgery revealed good ureteral patency (Fig. 2).

Case 2: A 45-year-old man presented with a 1-cm ureteral stone located at the pelvic brim after failure of two sessions of ESWL. The patient was scheduled for ureteroscopy with a Storz 9.5 Fr semi-rigid ureteroscope and pneumatic lithotripsy (Elmed Vibrolith, Elmed Lithotripsy Systems, Ankara, Turkey). No guidewires could be advanced into the proximal collecting system. Endoscopic lithotripsy of the stone was then performed, leaving behind a relatively small impacted fragment of the stone. A basket catheter was placed behind the stone fragment, and was used to retrieve it as gently as possible; however, the stone could not be pulled out. Intraoperative retrograde pyelogram performed at this time revealed extravasation of the contrast material, suggesting ureteral avulsion.

The retroperitoneum was explored through a midline abdominal incision, and a short segment (1 cm) of devitalized mid-ureteral segment was recognized. After careful mobilization of the viable distal and proximal ureteric ends, an end-to-end wide spatulated and stented ureteral anastomosis was performed without complications.

Case 3: A 36-year-old woman was referred from another center with right flank pain, tenderness, and fever five days after a ureterorenoscopic attempt to treat a 1-cm ureteral stone about 2 cm distal to the ureteropelvic junction. The patient was told that there was a narrow ureteric segment proximal to the intramural ureter, which made ureterorenoscopic access to the stone impossible. The patient was then scheduled for outpatient ESWL treatment. Distal ureteral avulsion was recognized five days later because of persistent fever, right flank pain, and urinoma on ultrasound. A percutaneous nephrostomy was placed immediately, and antegrade pyelogram showed a large defect of the mid-ureter (Fig. 3).

Surgery was performed three weeks after clinical stabilization with parenteral antibiotics. Through a muscle-splitting right foley incision, the proximal end of the ureter was identified, and was extensively adherent to the duodenum and the psoas fascia inferior to the lower pole of the right kidney. It was dissected and mobilized proximally (Fig. 4). The proximal ureteral stone was identified and extracted

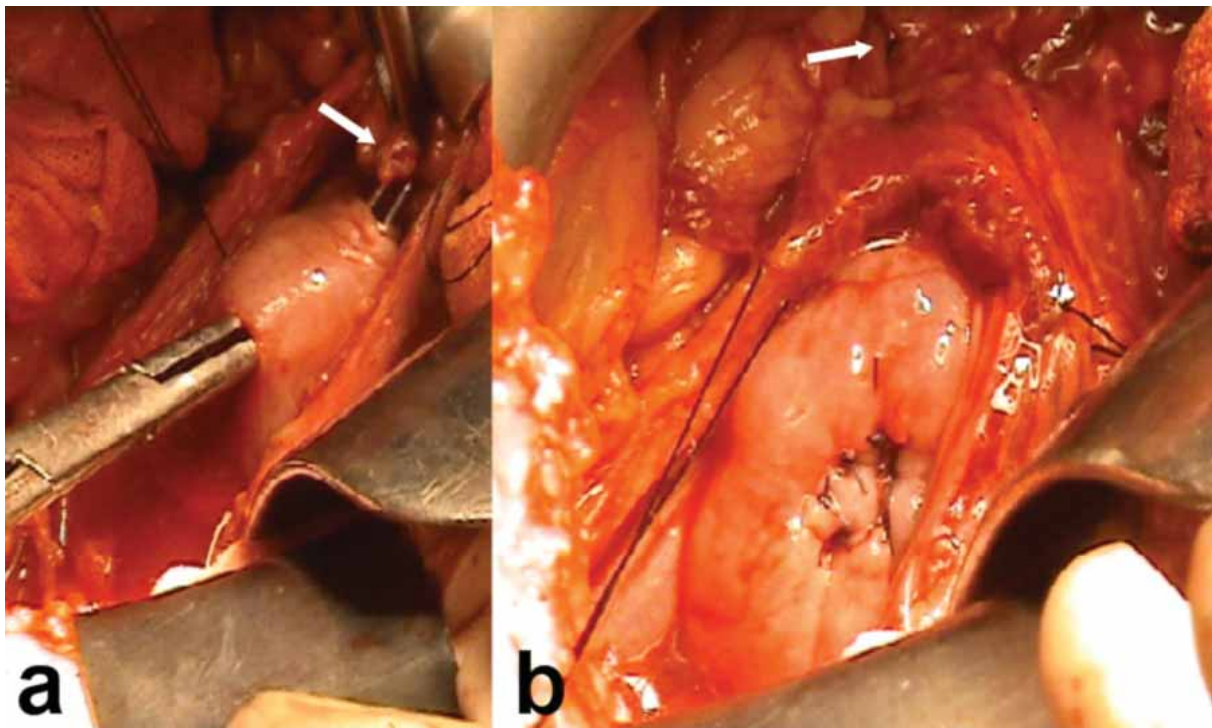


Figure 1 (a) Transfer of the right ureter (arrow) through the submucosal tunnel which is created in the right dome of the bladder. (b) The mobilized right ureter is gently fixed to the psoas fascia.

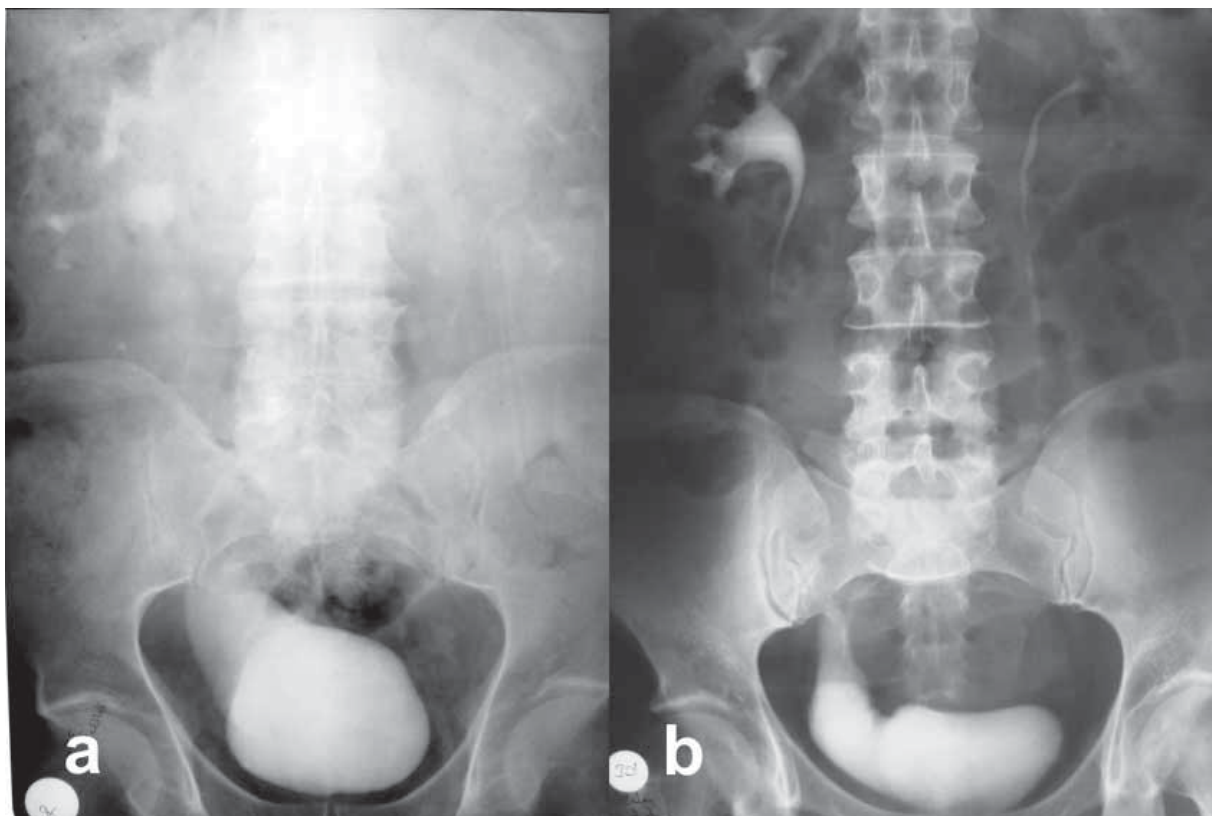


Figure 2 Late radiological evaluation demonstrating patency of the ureter without evidence of dilatation six months postoperatively. (a) Psoas hitch, (b) Boari flap.

through a ureterotomy. The 7-cm ischemic segment of the midureter was then resected. Then, through a Pfannenstiel incision, a 17-cm Boari flap was raised

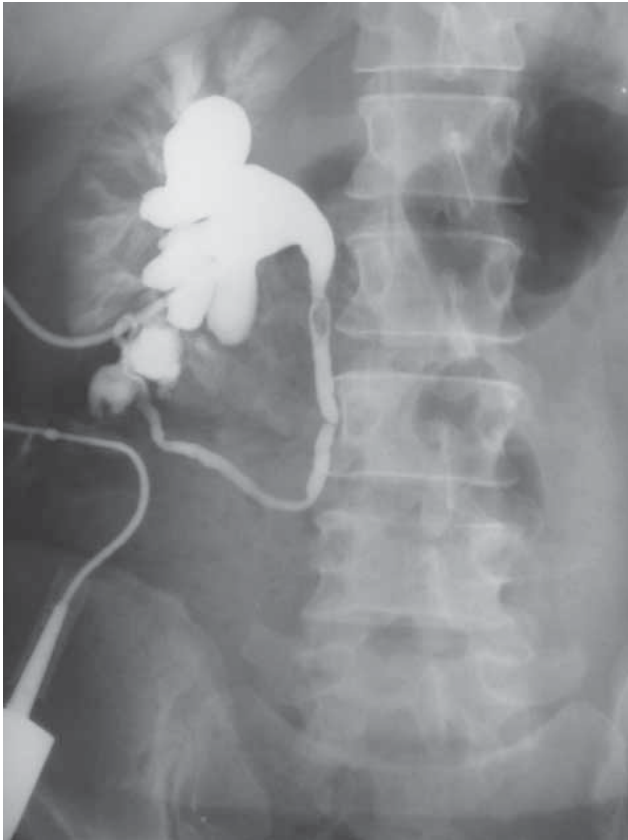


Figure 3 Antegrade pyelogram showing a large ureteral avulsion defect in the midureter, and stone (filling defect) in the proximal ureter.

from the bladder (Fig. 5a), followed by transfer of the proximal ureteric end from the retroperitoneum to the pelvic region, non-refluxing anastomosis of the Boari flap to the right ureter, and tubularization and fixation of the Boari flap to the upper psoas fascia (Fig. 5b).

Results

Recovery was uneventful and the ureteral stent was removed within six weeks after the repair in all cases. IVP was obtained six months postoperatively in order to assess the patency of the ureter. All patients were followed for at least 18 months after the reconstruction. There was no evidence of dilatation or strictures within the postoperative follow-up period in any of the three cases (Fig. 2).

Discussion

Ureterorenoscopy is a powerful tool for treating upper urinary tract pathology such as ureteral or kidney stones, ureteral strictures, uretero-pelvic obstruction, and upper tract transitional cell carcinoma. It is also useful in the evaluation of hematuria. Ureterorenoscopy can be used both in adults and in children. With the significant technological advancement and worldwide use of the ureteroscope, the incidence of complications due to ureteroscopy has decreased; however, we can still experience significant complications that may result in significant morbidity or even mortality.^[4]

Most complications of ureterorenoscopy are classified as minor, for which close observation or minor

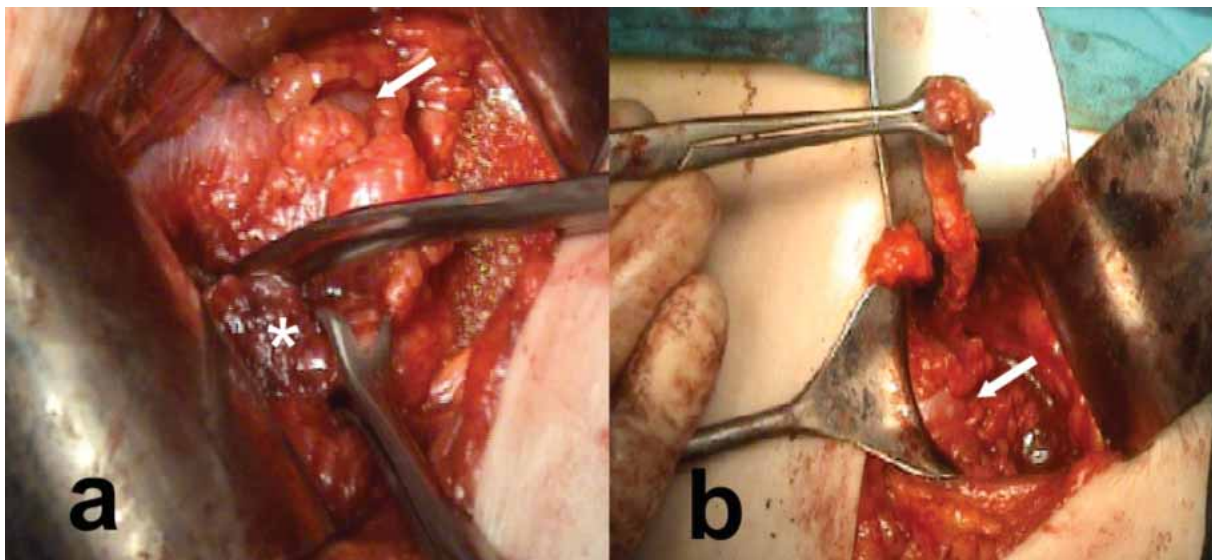


Figure 4 (a) Dissection of the right midureteric end (asterisk), which is severely adherent to retroperitoneal structures inferior to the lower pole of the right kidney (arrows). (b) Final appearance of the ureter following mobilization up to the renal hilum.

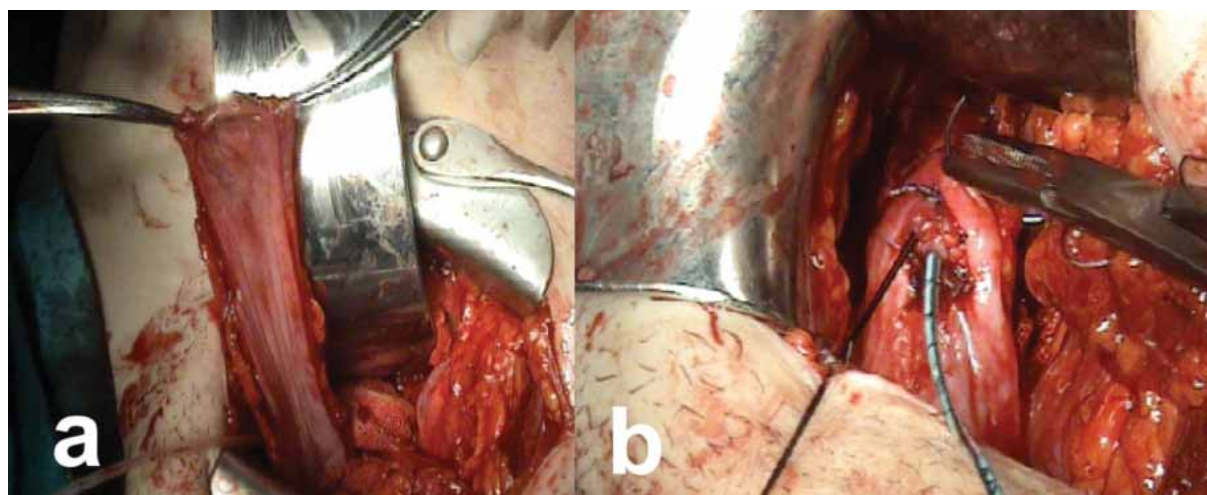


Figure 5 (a) The extended Boari flap, which is raised from the mobilized right bladder dome. (b) Ureterovesical anastomosis is complete, and the flap will be tubularized with continuous suturing.

interventions usually suffice. Major complications may, however, require more advanced procedures to prevent serious consequences. Ureteroscopic complications can be classified as intraoperative, early onset, or late onset, and as minor or major complications. Ureteral avulsion and ureteral intussusceptions are major intraoperative complications, whereas ureteral perforation, ureteral false passage, mucosal abrasion, urine extravasation, thermal injury, bleeding, and difficult access are regarded as minor complications. Early postoperative major complications include infection, sepsis, and development of stone street. Early postoperative minor complications include ureteral obstruction, accompanying colic pain due to a clot or edema, and vesicoureteral reflux. The only significant late complication is the formation of ureteral strictures, which is classified as a major complication.^[5]

Complete ureteral avulsion is among the most catastrophic complications of ureterorenoscopic surgery, and necessitates immediate open or endoscopic intervention in almost every case. Generally, excessive force during withdrawal of a stone with a basket catheter is the cause of avulsion. The injury is recognized as the distal portion of the ureter is withdrawn with the stone as it exits the urethra in a female, or when the avulsed ureter is visualized outside the ureteral orifice in a male patient.^[5] If the avulsion is not recognized at surgery, late diagnosis occasionally is suggested by the presence of fever, flank pain, abdominal tenderness, and/or flank mass, indicating a retroperitoneal urinoma or abscess secondary to leakage of urine,^[6] as was evident in our third case.

Complete avulsion of the ureter is a rare complication, which occurred in 2 out of 452 patients (0.4%) in our own series. Stoller and Wolf's review of 33 published series between 1984 and 1992, including 5117 patients, revealed 17 avulsions, for an approximate incidence of 0.3%.^[7] Grasso reviewed 3 series including 1059 patients and no avulsions were reported.^[8] Surgical repair of this complication is a challenge, and varies significantly according to the level of the injury. Ureteroneocystostomy can suffice in distal ureter injuries, whereas a Boari flap or psoas hitch may be needed in avulsions proximal to the middle third of the ureter. Proximal ureteral injuries can be treated with end-to-end anastomosis in the absence of devitalization. If there is devitalization in a proximal ureteric avulsion, more extreme measures may be warranted, such as ileal ureteric replacement or even renal auto-transplantation.^[9,10] Nephrectomy can be an option if the patient is undergoing a more complex and life-threatening operation.^[8] Invariably, the best outcome is achieved in patients who are diagnosed immediately, because the extent of the devitalized ureteral segment is usually more limited. If the injury is not identified immediately, or if the patient would benefit from further preparation or stabilization, a percutaneous nephrostomy should be placed until definitive repair can be undertaken.^[5]

In our series, each patient underwent a different surgical repair. An end-to-end spatulated anastomosis was possible in one of our cases with an impacted stone at the pelvic brim. Another patient presenting with two impacted stones underwent a psoas hitch and non-refluxing ureterovesical anastomosis. The

last patient, who had a late diagnosis, had a long ischemic and devitalized ureteral segment. This patient required two different incisions with mobilization and excision of the devitalized ureteric segment in the retroperitoneum, followed by preparation of an extended Boari flap and tension-free non-refluxing uretero-vesical anastomosis. As understood from the present study, there are several factors including age of the patient, kidney function, level of the injury, length of the ureteral defect, and the surgeon's experience, which determine the best approach for the individual case.^[11]

Other factors determining the treatment options which are not directly related to the specifics of the avulsion, include the presence of cancer, infection, retroperitoneal fibrosis, vascular graft, and previous radiation exposure, as well as the patients' overall medical condition and preferences.^[12] Furthermore, adequate ureteral restoration after successful reconstructive intervention is by no means free of complications. Complication rates after ureteric restoration vary from 11% to 53% despite the fact that most cases can readily be handled endoscopically or through reoperation.^[13-15] Following surgical reanastomosis, we did not experience any early or late procedure-related complications, which may be attributed to our strict care in creating a wide and tension-free anastomosis.

In conclusion, repair of complete ureteral avulsion following endoscopic surgery is a rare but challenging task, for which should be tailored to the individual situation. Boari flap is a versatile technique in the repair of severe ureteral defects, and may eliminate the need for a possible ileal ureteric replacement. Nevertheless, proper ureterorenoscopic handling is the key for the prevention of this catastrophic complication. The use of a safety guidewire during ureteroscopy is always advisable, because it enables the surgeon to place a ureteral stent in case of a partial ureteral injury, which may allow the injury to heal within 4 to 6 weeks of the attempt, and may eliminate the need for further invasive procedures. If a ureteral stent cannot be negotiated safely beyond the injury, a percutaneous nephrostomy should be placed, and antegrade stent placement should be attempted.^[7] Ureteral baskets should be used cautiously, avoiding excessive pulling forces, especially during ureterorenoscopic management of impacted stones.

References

1. Young HH, McKay RW. Congenital valvular obstruction of the prostatic urethra. *Surg Gynecol Obstet* 1929;48:509.
2. Marshall VF. Fiber optics in urology. *J Urol* 1964;91:110-4.
3. Goodman TM. Ureteroscopy with pediatric cystoscope in adults. *Urology* 1977;9:394.
4. de la Rosette JJ, Skrekas T, Segura JW. Handling and prevention of complications in stone basketing. *European Urology* 2006;50:991-9.
5. Johnson DB, Pearle MS. Complications of ureteroscopy. *Urol Clin N Am* 2004;31:157-71.
6. Martin X, Ndoye A, Konan PG, Feitosa Tajra LC, Gelet A, Dawahra M et al. Hazards of lumbar ureteroscopy: apropos of 4 cases of avulsion of the ureter. *Prog Urol* 1998;8:358-62.
7. Stoller ML, Wolf JS. Endoscopic ureteral injuries. In: McAninch JW, editor. *Traumatic and reconstructive urology*. Philadelphia: WB Saunders; 1996. p. 199-211.
8. Grasso M. Complications of ureteropyloscopy. In: Taneja SS, Smith RB, Ehrlich RM, editors. *Complications of urologic surgery*. 3rd edition. Philadelphia: WB Saunders; 2001. p. 268-76.
9. Chang SS, Koch MO. The use of an extended spiral bladder flap for treatment of upper ureteral loss. *J Urol* 1996;156:1981-3.
10. Shokeir AA. Interposition of ileum in the ureter: a clinical study with long-term follow-up. *Br J Urol* 1997; 79:324-7.
11. Alapont JM, Broseta E, Oliver F, Pontones JL, Boronat F, Jiménez-Cruz JF. Ureteral avulsion as a complication of ureteroscopy *Int Braz J Urol* 2003;29:18-23.
12. St Lezin MA, Stoller ML. Surgical ureteral injuries. *Urology* 1991;38:497-506.
13. Selzman AA, Sprinak JP. Iatrogenic ureteral injuries: a 20-year experience in treating 165 injuries. *J Urol* 1996;155:878-81.
14. Higgins CC. Ureteral injuries during surgery: a review of 87 cases. *JAMA* 1967;199:82-8.
15. Ghali AM, El Malik EM, Ibrahim AI, Ismail G, Rashid M. Ureteric injuries: diagnosis, management, and outcome. *J Trauma* 1999;46:150-8.

Correspondence (Yazışma): Uzm. Dr. Fikret Fatih Önel. Sakarya Training and Research Hospital, Adnan Menderes Cd. 54100 Sakarya, Turkey
Tel: +90533-514 10 99 e-mail: ffonol@yahoo.com