



22-year survival following radical nephrectomy and several metastasectomies in a case of renal cell carcinoma

Radikal nefrektomi ve çoklu metastazektomiler sonrası 22 yıl sağkalım sağlanan böbrek karsinomu vakası

Ömer Barış Yücel¹, Hayri Murat Tunç¹, Mert Başaran², Necdet Aras¹

ABSTRACT

Renal cell carcinoma (RCC) is a common malignancy. Metastases can be seen both synchronously, at the time of diagnosis, and metachronously during follow-up. At the time of diagnosis, 23% of the patients have metastatic disease. and 25% of patients will develop metastasis during follow-up period after nephrectomy. Nearly 80% of them develop within the first 5 years. However late metastasis of RCC have been also reported within the postoperative 10 years in the literature. For metastatic lesions, if surgically feasible, metastasectomy, and targeted pharmaceutical agents have been recommended. However any randomized controlled study which aimed to determine treatment protocol in patients who develop multiple metastases has not been cited in the literature. Herein, we are presenting a case with renal cell carcinoma in whom within 22 years of follow-up after 10 years of survival multiple metastases in different organs were detected which were managed with surgical, and medical treatments. As far as we know, this case is the first patient with the longest survival whose non-pulmonary metastases had been treated with more than one surgical interventions.

Keywords: Metastasis; metastasectomy; renal cell carcinoma.

ÖZ

Böbrek hücreli karsinom, sık görülen bir kanserdir. Gerek tanı anında (senkron) gerekse takip sırasında (metakron) metastaz görülebilir. Tanı anında hastaların yaklaşık %23'ü metastatik hastalığa sahiptir, takip sırasında da %25 hastada metastaz gelişmesi beklenir. Bunların yaklaşık %80'i ilk 5 yılda gelişse de, on yıl sonrasında da bildirilen geç metastazlar vardır. Metastatik lezyonlar için, cerrahi açıdan mümkün olduğu sürece metastazektomi ve hedefe yönelik ajanlar önerilmektedir, ancak izlem sırasında saptanan çoklu metastazda tedavi protokolünü belirlemek için randomize kontrollü bir çalışma literatürde bulunmamaktadır. Yirmi iki yıllık takip süresince 10 yıllık hastaliksız sağkalım sonrası, farklı organlarda saptanan çoklu metastazları cerrahi ve medikal yöntemlerle tedavi edilen bu vaka, bildiğimiz kadari ile akciğer dışı metastazları, birden çok cerrahi ile tedavi edilen, en uzun sağkalımlı hastadır.

Anahtar Kelimeler: Metastaz; metastazektomi; böbrek hücreli karsinom.

Introduction

Renal cell carcinoma (RCC) is a common malignancy and represents 2-3% of all cancers in adults.^[1] At the time of diagnosis 23% of the patients have metastatic disease.^[2] Untreated patients with metastatic cancer have a median survival of 6 to 12 months and a 5-year survival rate less than 20 percent.^[3] Twenty-five percent of the patients will develop metastasis after nephrectomy and the majority (78%) of recurrent RCC occurs within the first five

years. Patients with synchronous metastasis have significantly shorter survival than patients with metachronous metastasis.^[4] Late metastasis of RCC have also been reported in the literature. "Late" is defined as ≥ 10 years after nephrectomy. Systemic therapy for metastatic disease (sunitinib and pazopanib, bevacizumab with IFN- α , temsirolimus as first-line therapy; axtinib, pazopanib or sorafenib as second-line treatment) should be recommended but there is no clear recommendation for the optimal treatment strategies for patients who developed

¹Department of Urology, Istanbul University Istanbul School of Medicine, Istanbul, Turkey

²Department of Medical Oncology, Oncology Institute, Istanbul University Istanbul School of Medicine, Istanbul, Turkey

Submitted:
07.03.2016

Accepted:
27.08.2016

Available Online Date:
18.04.2017

Correspondence:
Ömer Barış Yücel
E-mail:
omerbarisyuel@gmail.com

©Copyright 2017 by Turkish Association of Urology

Available online at
www.turkishjournalofurology.com

metachronous metastasis after radical nephrectomy during the follow up period. Metastasectomy and several targeted drugs are the possible treatment options. There is no randomized clinical trial which analyzed the effect or timing of metastasectomy or medical therapy for recurrent metastasis of renal cell carcinoma, but longer survival rates with complete metastasectomy have been reported.

Here we present a patient, who after 10 years of disease-free survival following radical nephrectomy had developed multiple metastases to different sites during the long follow-up period. These metastases were treated with metastasectomies and medical therapy and then the patient experienced a very long-term survival and high quality of life. To our knowledge, this is the only patient reported in the English literature, with ≥ 20 years of survival after nephrectomy and multiple cured non-pulmonary metastases. We aim to highlight the importance of follow up in RCC patients for diagnosing late metastases and to summarize the treatment options.

Case presentation

A 57-year-old woman was admitted to the urology clinic with macrohematuria and pain at the right flank. An abdominal ultrasonography and computed tomography (CT) ruled out other possibilities, and a 10×8×7 cm tumor in the right kidney was diagnosed. Radical nephrectomy was performed in February 1995, the histopathology of the specimen was reported a Fuhrman grade 2 and pT2 clear cell RCC. After an 8 years of disease-free interval, in November 2003, bilateral total thyroidectomy was performed for multiple nodules, and the pathologic diagnosis was metastasis of RCC (Figure 1). One year after, at the 9th year of the follow-up period, multiple nodules in pancreas were diagnosed in abdominal CT, then duodenectomy, total pancreatectomy and splenectomy were performed. Metastases from RCC were detected in pancreas, whereas duodenum and spleen were cancer-free. She presented two years later with neck pain. An excisional biopsy was performed in April 2006 for 1.5 cm mass in neural foramen of cervical vertebrae (C4-C5) and the pathologic diagnosis was RCC metastasis. After 2 cycles of interleukin-2 treatment, a hemilaminectomy, partial facetectomy and tumor debulking surgery of the left C4-C5 vertebrae were performed and sorafenib treatment was given for 13 months. The patient reported serious side effects of sorafenib such as exfoliation of skin, pruritus, palmar plantar erythrodysesthesia, and skin rash. In October 2007, a recurrent metastasis in C6-C7 vertebrae was diagnosed. For the metastatic disease on the C6 nerve root and invasion to the C6-C7 vertebrae, a total facetectomy and complete metastasectomy were performed and RCC metastasis with negative surgical margin was reported. Sunitinib treatment was considered, but the patient denied the treatment because of the possible side effects of the drug. After six years of disease-free interval, in October 2013,

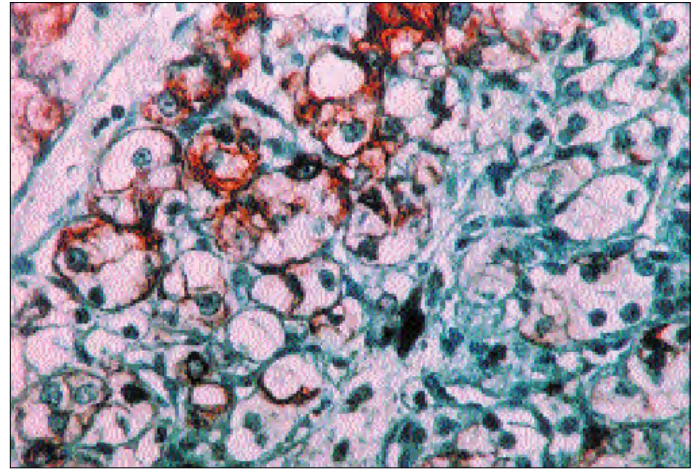


Figure 1. Vimentin- positive tumor cells (Vimentin x 400)

the patient admitted to the urology department with hip pain. A 6 cm soft tissue mass in the left gluteal area was detected and excised. The pathology report was metastasis of a Fuhrman grade 2 RCC, with negative surgical margin. After one year disease-free interval, in December 2015, metastatic lesions in the liver were detected. Due to infeasibility of the metastasectomy, pazopanib treatment was considered, and under this treatment progression of the liver metastases was not observed. The patient was admitted to the neurosurgery department in June 2016 with back pain. Two masses in the vertebral corporal bodies (T4-T7) were detected and corpectomies of T4 and T7 were performed. The pathology report was metastasis of a RCC. The pazopanib treatment will be continued, and the patient is still alive.

Discussion

Renal cell carcinoma is a relatively common disease. At the time of diagnosis around 25% of the patients have metastatic disease and 25% of them will develop metastasis metachronously, mostly within the first five years after nephrectomy. Scoring systems and nomograms based on size and stage of the primary tumor, extent of lymph node involvement, and tumor histology have been used to predict the risk of development of metastases. Some authors argue that follow-up with imaging for low-risk disease might not be cost-effective, but late metastases of RCC have been reported.^[1] The incidence of late recurrence is 11% in patients surviving for 10 years and the longest interval to recurrence reported is 45 years.^[5,6] Long term survival rates of 21-44% have been documented following curative resection for RCC metastases at various sites.^[7]

Metastases from renal cell carcinoma can be diagnosed in virtually any location, but they commonly spread to the lung (75%), regional lymph nodes (60-65%), bones (20%), liver (18%), skin (8%), and central nervous system (8%).^[3]

The bone is the second common site of distant metastasis. Osseous metastases are mostly lytic, hypervascular and highly destructive lesions with high risks of fracture. They are difficult to manage and associated with pain and a low quality of life for the patient.^[8-10] The 5-year survival after osseous metastasectomy is around 20% and the surgery should be considered if feasible. Radiotherapy can be also considered, especially for the management of pain.^[1,3] The patient in our case has long-term tumor-free survival after surgical removal of osseous metastases.

Rarely metastases from RCC to the spinal cord have been reported. Patients with intradural metastases have a mean survival of 11 months without treatment but long-term outcomes with complete surgical resection of nerve root metastases are possible.^[11]

Metastatic lesions to the pancreas are uncommon. Only 2% of pancreatic cancers are metastatic and they are most frequently from RCC.^[12,13] They are mostly asymptomatic lesions which could be detected many years after nephrectomy. Metastasectomy should be the choice of treatment because these lesions are surgically curable with a long-term survival.^[14]

The thyroid gland is an atypical site for metastasis from RCC and a 5% of RCC metastases develops during the follow up, even many years after the primary disease of the thyroid gland. Five-year survival rate increases up to 80 percent. A long cancer-free interval and complete resection of the metastasis are the prognostic factors for long-term survival.^[15]

The liver is less often involved in metastatic RCC. Five-year overall survival rate after metastasectomy was 62 percent. Patients benefit from resection of liver metastases if technically feasible.^[16]

There is no randomized clinical trial concerning the effect of metastasectomy but improved survival with complete resection of metastatic lesions has been reported in several series.^[17-19] Kavolius et al.^[20] reported male gender, disease-free interval of >1 year, complete metastasectomy and single metastatic focus as independent predictive factors of survival.

In conclusion, patients undergoing surgery for localized RCC remain at long-term risk of disease recurrence, even they had a low-risk disease and they should be informed about the risk of metastases in the long term. With early diagnosis and complete surgical resection, a long-term survival may be achieved. Metastasectomy or targeted therapies in patients with recurrent RCC has never been analyzed in clinical randomized studies. Complete resection of metastases should be performed if feasible. Patients should be considered for multimodal therapy. To our knowledge, this is the only patient in the English literature, with ≥ 20 years of survival after nephrectomy and multiple cured non-pulmonary metastases.

Informed Consent: Written informed consent was obtained from patients who participated in this case.

Peer-review: Externally peer-reviewed.

Author Contributions: Concept – N.A.; Design – Ö.B.Y.; Supervision – H.M.T., N.A.; Resources – Ö.B.Y.; Materials – N.A.; Data Collection and/or Processing – N.A., Ö.B.Y., M.B.; Analysis and/or Interpretation – N.A., H.M.T.; Literature Search – Ö.B.Y.; Writing Manuscript – Ö.B.Y.; Critical Review – N.A., H.M.T., M.B.

Conflict of Interest: No conflict of interest was declared by the authors.

Financial Disclosure: The authors declared that this study has received no financial support.

Hasta Onamı: Yazılı hasta onamı bu olguya katılan hastalardan alınmıştır.

Hakem Değerlendirmesi: Dış bağımsız.

Yazar Katkıları: Fikir – N.A.; Tasarım – Ö.B.Y.; Denetleme – H.M.T., N.A.; Kaynaklar – Ö.B.Y.; Malzemeler – N.A.; Veri Toplanması ve/veya İşlemesi – N.A., Ö.B.Y., M.B.; Analiz ve/veya Yorum – N.A., H.M.T.; Literatür Taraması – Ö.B.Y.; Yazıyı Yazan – Ö.B.Y.; Eleştirel İnceleme – N.A., H.M.T., M.B.

Çıkar Çatışması: Yazarlar çıkar çatışması bildirmemişlerdir.

Finansal Destek: Yazarlar bu çalışma için finansal destek almadıklarını beyan etmişlerdir.

References

1. Ljungberg B, Bensalah K, Canfield S, Dabestani S, Hofmann F, Hora M, et al. EAU guidelines on renal cell carcinoma: 2014 update. *Eur Urol* 2015;67:913-24. [CrossRef]
2. Ritchie AW, deKernion JB. The natural history and clinical features of renal carcinoma. *Semin Nephrol* 1987;7:131-9.
3. Ljungberg B. The role of metastasectomy in renal cell carcinoma in the era of targeted therapy. *Curr Urol Rep* 2013;14:19-25. [CrossRef]
4. Eggener SE, Yossepowitch O, Kundu S, Motzer RJ, Russo P. Risk score and metastasectomy independently impact prognosis of patients with recurrent renal cell carcinoma. *J Urol* 2008;180:873-8. [CrossRef]
5. Tapper H, Klein H, Rubenstein W, Intriore L, Choi Y, Kazam E. Recurrent renal cell carcinoma after 45 years. *Clin Imaging* 1997;21:273-5. [CrossRef]
6. McNichols DW, Segura JW, DeWeerd JH. Renal cell carcinoma: long-term survival and late recurrence. *J Urol* 1981;126:17-23.
7. Featherstone JM, Bass P, Cumming J, Smart CJ. Solitary, late metastatic recurrence of renal cell carcinoma: two extraordinary cases. *Int J Urol* 2006;13:1525-7. [CrossRef]

8. Kollender Y, Bickels J, Price WM, Kellar KL, Chen J, Merimsky O, et al. Metastatic renal cell carcinoma of bone: indications and technique of surgical intervention. *J Urol* 2000;164:1505-8. [\[CrossRef\]](#)
9. Lin PP, Mirza AN, Lewis VO, Cannon CP, Tu SM, Tannir NM, et al. Patient survival after surgery for osseous metastases from renal cell carcinoma. *J Bone Joint Surg Am* 2007;89:1794-801. [\[CrossRef\]](#)
10. Kato S, Murakami H, Takeuchi A, Demura S, Yoshioka K, Kawahara N, et al. Fifteen-year survivor of renal cell carcinoma after metastasectomies for multiple bone metastases. *Orthopedics* 2013;36:e1454-7.
11. Jost G, Zimmerer S, Frank S, Cordier D, Merlo A. Intradural spinal metastasis of renal cell cancer. Report of a case and review of 26 published cases. *Acta Neurochir (Wien)* 2009;151:815-21. [\[CrossRef\]](#)
12. Adsay NV, Andea A, Basturk O, Kilinc N, Nassar H, Cheng JD. Secondary tumors of the pancreas: an analysis of a surgical and autopsy database and review of the literature. *Virchows Arch* 2004;444:527-35. [\[CrossRef\]](#)
13. Ballarin R, Spaggiari M, Cautero N, De Ruvo N, Montalti R, Longo C, et al. Pancreatic metastases from renal cell carcinoma: the state of the art. *World J Gastroenterol* 2011;17:4747-56. [\[CrossRef\]](#)
14. Moletta L, Milanetto AC, Vincenzi V, Alaggio R, Pedrazzoli S, Pasquali C. Pancreatic secondary lesions from renal cell carcinoma. *World J Surg* 2014;38:3002-6. [\[CrossRef\]](#)
15. Ramírez-Plaza CP, Domínguez-López ME, Blanco-Reina F. Thyroid metastasis as initial presentation of clear cell renal carcinoma. *Int J Surg Case Rep* 2015;10:101-3. [\[CrossRef\]](#)
16. Staehler MD, Kruse J, Haseke N, Stadler T, Roosen A, Karl A, et al. Liver resection for metastatic disease prolongs survival in renal cell carcinoma: 12-year results from a retrospective comparative analysis. *World J Urol* 2010;28:543-7. [\[CrossRef\]](#)
17. Russo P. Multi-modal treatment for metastatic renal cancer: the role of surgery. *World J Urol* 2010;28:295-301. [\[CrossRef\]](#)
18. Kierney PC, van Heerden JA, Segura JW, Weaver AL. Surgeon's role in the management of solitary renal cell carcinoma metastases occurring subsequent to initial curative nephrectomy: an institutional review. *Ann Surg Oncol* 1994;1:345-52. [\[CrossRef\]](#)
19. Alt AL, Boorjian SA, Lohse CM, Costello BA, Leibovich BC, Blute ML. Survival after complete surgical resection of multiple metastases from renal cell carcinoma. *Cancer* 2011;117:2873-82. [\[CrossRef\]](#)
20. Kavolius JP, Mastorakos DP, Pavlovich C, Russo P, Burt ME, Brady MS. Resection of metastatic renal cell carcinoma. *J Clin Oncol* 1998;16:2261-6. [\[CrossRef\]](#)